

CASE REPORT

PARRY ROMBERG'S SYNDROME: A CASE REPORT

Manisha Nijhwan¹, Shifa Yadav², Dinesh Mathur³, Savitha Agrwal⁴, Shilpa Soni⁵

HOW TO CITE THIS ARTICLE:

Manisha Nijhwan, Shifa Yadav, Dinesh Mathur, Savitha Agrwal, Shilpa Soni. "Parry Romberg's Syndrome: A Case Report". Journal of Evolution of Medical and Dental Sciences 2014; Vol. 3, Issue 44, September 15; Page: 10898-10902, DOI: 10.14260/jemds/2014/3422

ABSTRACT: We are reporting 18 year old female patient presented with facial asymmetry of right side of face with thinning of skin on right side of face. Patient also had multiple hyperpigmentation patches on right side of trunk and neck with right sided tongue atrophy. Radiological findings showed minimal right sided frontal lobe atrophy of brain. All these findings were suggestive of parry Romberg's syndrome. We hereby are presenting a case of Parry-Romberg syndrome with classical features along with radiological and histopathological findings.

INTRODUCTION: Parry-Romberg syndrome (PRS) also known as "progressive facial hemiatrophy" is characterized by a progressive but self-limited atrophy of the skin and subcutaneous tissue on one side of the face.^[1,2] PRS was first reported by Parry and then described as a syndrome by Romberg.^[3,4] There is a progressive wasting of subcutaneous fat, sometimes accompanied by the atrophy of skin, muscle, cartilage, bone, and muscle.^[5]

It overlaps with a condition known as linear scleroderma "en coup de sabre".^[6] In most of the cases atrophy is usually confined to one side of the face and cranium; however it may occasionally spread to the neck and one side of the body.^[7,8] The onset is insidious and the condition usually manifests in the first or the second decade of life with skin changes resembling scleroderma.^[9] It is usually accompanied by neurological complications like trigeminal neuralgia, migraine, seizures and changes in the eyes and hair.^[11,13]

Partial seizures have been found to be most common neurological complication.^[10] The aetiology of this condition is unclear.^[16,11] Many theories have been postulated to explain this rare disease like autoimmunity, trigeminal theory etc.^[2] Hemifacial atrophy occurs sporadically and some familial distribution has been found.^[18] The disease is common in females and the male to female ratio is 3:2.^[5] Ocular involvement is common and the most frequent manifestation is enophthalmos.^[13] In this case report we present a case of a Parry-Romberg syndrome.

CASE DESCRIPTION AND RESULTS: An 18 year old female patient reported to the Department of Dermatology Venereology and Leprosy, Mahatma Gandhi Hospital, Jaipur, Rajasthan, with the complaint of facial asymmetry of right side of face with thinning of skin on right side of face and multiple hyperpigmentation patches on right side of neck and trunk. There were no associated symptoms. The patient's medical and family history was noncontributory. Skin examination showed facial asymmetry of right side (Figure 1).

The right eye was depressed in the socket (enophthalmos along with scanty lower eyelashes (Figure 2). There was a deviation in angle of mouth to the affected side. Pigmentation was noticed on the right side of the neck and trunk area (Figure 3). The upper left border of the right side lips showed atrophy. The intraoral examination revealed the atrophy of tongue on the right side and angular cheilitis on the same side (Figure 4).

CASE REPORT

Routine blood investigations were carried out which revealed all values within normal limits. X ray skull was normal (Figure 5). In MRI there was slight atrophy of the right frontal lobe of brain with no other changes (Figure 6). Biopsy from the hyper pigmented lesion on the trunk showed sparse superficial and deep perivascular lymphocytic infiltrate with flattening of epidermal rete pattern.

Reticular dermal collagen was thinned at places and arranged parallel to the surface epidermis. The sweat units were present in mid reticular dermis. These findings were consistent with scleroderma (Figure 7). Based on the clinical features, histopathological and radiological findings a diagnosis of Parry- Romberg syndrome was made.

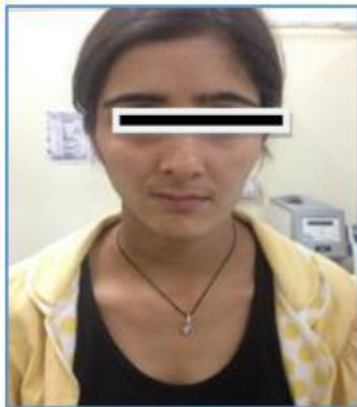


Fig. 1: Right sided facial hemiatrophy and facial asymmetry

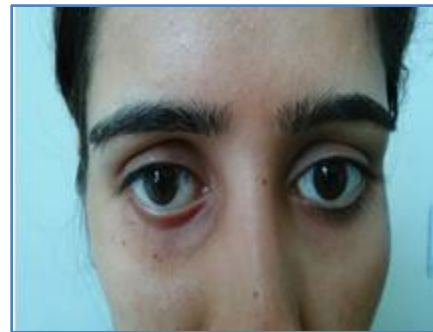


Fig. 2: Right side denophthalmos along with scanty lower eyelashes

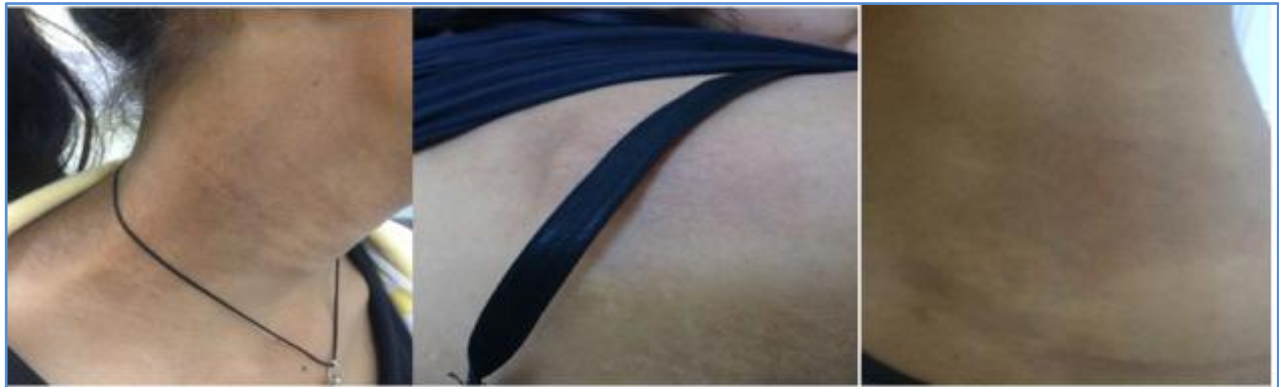

Fig. 3: Hyper pigmented brown colored patches on right side of neck and trunk area

CASE REPORT

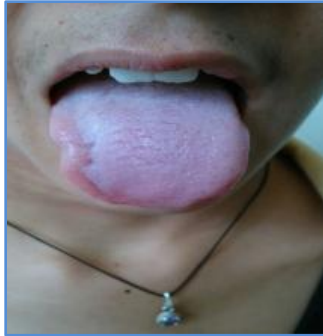

Fig. 4: Right sided tongue atrophy along with deviation of tongue towards the affected side

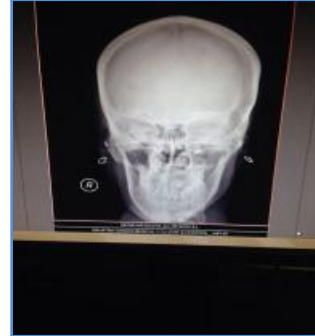

Fig. 5: Normal x ray skull

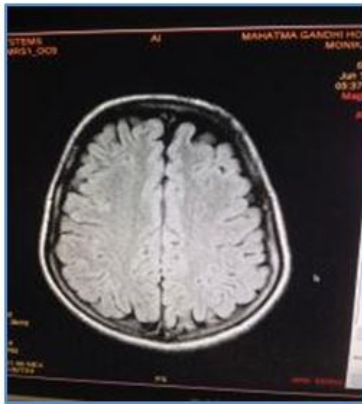

Fig. 6: MRI of brain showing slight atrophy of left frontal lobe

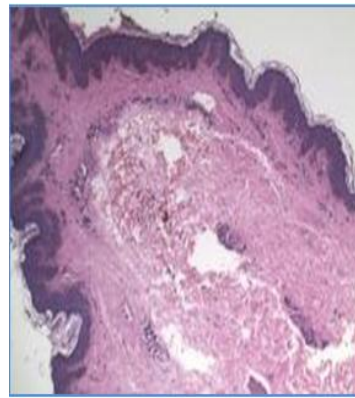


Fig. 7: Biopsy image showing findings of scleroderma

DISCUSSION: Parry Romberg syndrome is an uncommon degenerative and poorly understood condition.^[14] It is characterized by a slow and progressive unilateral atrophy of the facial tissues, including muscles, bones and skin.^[15,16] More than an aesthetic concern, this disease brings several functional and psychological problems due to asymmetry of the face.^[14]

The condition is more often found in female population and has predilection for the left side of the face.^[5] Our case was a female girl presented with right sided facial hemiatrophy. The prevalence rate is estimated to be at least 1 per 700.000 in the general population ^[6]. In our case, there was involvement of right side of the face, neck and trunk. The most important features of this disease are enophthalmos, the deviation of mouth and nose to the affected side, and lips involvement,^[17] which were also found in our case.

Clinically, the skin can be dry and hyper pigmented,^[14] which is also seen in presented case. Some patients present with demarcation line between normal and abnormal skin, known as “coup de sabre” (French term which means “cut of the sword”)^[6,14] which was not seen in our case. Our patient also presented with atrophy of the tongue on right side in consistent with the findings mentioned by Da Silva- Pinheiro TP et al.^[14]

CASE REPORT

The treatment is usually based on reposition of adipose tissue that was lost due to atrophy. Autogenous fat grafts, cartilage grafts, silicone injections and prostheses, bovine collagen and inorganic implants are some alternatives to aesthetic correction of the atrophy.^[18] Panfacial volumisation with autologous fat is an excellent tool for replacing volume and restoring contour to the aging face.^[19]

Our patient was suggested treatment using alloplastic implants to improve the facial appearance, but could not make up due to financial and logistical reasons. We have kept the patient on 30 mg prednisolone with weekly 7.5 mg methotrexate to stop the progression of disease along with local vitamin E oil application on the hyper pigmented region.

REFERENCES:

1. Padmini P, Singhi PD. Facial hemiatrophy. *Indian Pediatr.* 1992 Apr; 29(4): 505-7. [Medline: 1506105]
2. Gulati S, Jain V, Garg G. Parry Romberg syndrome. *Indian J Pediatr.* 2006 May; 73(5): 448-9. [Medline: 16741338] [doi: 10.1007/BF02758576]
3. Parry CH. *Collection From the Unpublished Medical Writings of the Late Calet Hillier Parry.* London, England: Under-woods; 1825: 478.
4. Romberg MH. *Trophoneurosen K liniske Ergenbrisse.* Berlin, Germany: Forster; 1846: 75-81.
5. Rogers BO. Progressive facial hemiatrophy: Romberg's disease: a review of 772 cases. *Proc 3d Int Cong Plast Surg. Excerpta Medica ICS.* 1964; 66: 681-689.
6. Stone J. Parry Romberg syndrome. *Practical Neurology* 2006; 6: 185-188. [doi: 10.1136/ jnnp.2006.089037]
7. Rogers BO: Embryology of the face and introduction to craniofacial anomalies. In: Converse JM editor. *Reconstructive Plastic Surgery*, 2nd ed. WB Saunders, Philadelphia; 1977. p. 2296-2358.
8. Hickman JW, Sheils WS. Progressive facial hemiatrophy. Report of a case with marked homolateral involvement. *Arch Intern Med.* 1964 May; 113: 716-20.9. [Medline: 14120599]
9. Mendonca J, Viana SL, Freitas F, Lima G. Late-onset progressive facial hemiatrophy (Parry-Romberg syndrome). *J Post- grad Med.* 2005 Apr-Jun; 51 (2): 135-6.11. [Medline: 16006711]
10. Asher SW, Berg BO. Progressive hemifacialatrophy: report of three cases, including one observed over 43 years, and computed tomographic findings. *Arch Neurol.*1982 Jan; 39 (1): 44-6. [Medline: 7055447]
11. Hakin KN, Yokoyama C, Wright JE. Hemifacial atrophy: an unusual cause of enophthalmos. *Br J Ophthalmol.* 1990 Aug; 74 (8): 496-7. [Medline: 2390527] [FREE Full Text] [doi: 10.1136/ bjo.74.8.496]
12. Witkop CJ. Genetic disease of the oral cavity: In Teiecke RW editor. New York, Mcgrant Hill 1965.
13. Kumar AA, Kumar RA, Shantha GP, Alogopinathan G. Progressive hemi facial atrophy - Parry Romberg syndrome presenting as severe facial pain in a young man: a case report. *Cases J.* 2009 Jul 2; 2: 6776. [Medline: 19829858] [FREE Full Text] [doi: 10.4076/1757-1626-2-6776]
14. Pinheiro TP, Silva CC, Silveira CS, Botelho PC, Pinheiro MG, PinheiroJde J. Progressive Hemifacial Atrophy--case report. *Med Oral Patol Oral Cir Bucal.* 2006 Mar 1; 11(2): E112-4. Review. [Medline: 16505785] [FREE Full Text]

CASE REPORT

15. Jurkiewicz MJ, Nahai F. The use of free revascularized grafts in the amelioration of hemifacial atrophy. *Plast Reconstr Surg.* 1985 Jul; 76(1): 44-55. [Medline: 4011779] [doi: 10.1097/00006534-198507000-00007]
16. Lakhani PK, David TJ. Progressive hemifacial atrophy with scleroderma and ipsilateral limb wasting (Parry-Romberg syndrome). *J R Soc Med.* 1984 Feb; 77(2):138-9. [Medline: 6737396] [FREE Full Text]
17. Pensler JM, Murphy GF, Mulliken JB. Clinical and ultra-structural studies of Romberg's hemifacial atrophy. *Plast Recon- str Surg.* 1990 May; 85(5): 669-74; discussion 675-6. [Medline: 2326349] [doi: 10.1097/00006534-199005000-00001]
18. 28. de la Fuente A, Jimenez A. Latissimusdorsi free flap for restoration of facial contour defects. *Ann Plast Surg.* 1989 Jan; 22(1):1-8. [Medline: 292340229] [doi: 10.1097/0000637-198901000-00001]
19. Donofrio LM. Panfacial volume restoration with fat. *Dermatol Surg.* 2005 Nov; 31(11Pt 2): 1496-505. [Medline: 16416631] [doi: 10.2310/6350.2005.31234]

AUTHORS:

1. Manisha Nijhwan
2. Shifa Yadav
3. Dinesh Mathur
4. Savitha Agrwal
5. Shilpa Soni

PARTICULARS OF CONTRIBUTORS:

1. Professor, Department of Dermatology, Venereology and Leprosy, Mahatma Gandhi Hospital, Jaipur, Rajasthan.
2. 2nd Year Resident, Department of Dermatology, Venereology and Leprosy, Mahatma Gandhi Hospital, Jaipur, Rajasthan.
3. Head of Department, Department of Dermatology, Venereology and Leprosy, Mahatma Gandhi Hospital, Jaipur, Rajasthan.

4. Senior Resident, Department of Dermatology, Venereology and Leprosy, Mahatma Gandhi Hospital, Jaipur, Rajasthan.
5. 1st Year Resident, Department of Dermatology, Venereology and Leprosy, Mahatma Gandhi Hospital, Jaipur, Rajasthan.

NAME ADDRESS EMAIL ID OF THE CORRESPONDING AUTHOR:

Dr. Manisha Nijhawan,
House No. 112,
Panchsheel Enclave,
J. L. M. Marg, Jaipur.
Email: m.nijhwan@gmail.com

Date of Submission: 01/09/2014.
Date of Peer Review: 02/09/2014.
Date of Acceptance: 09/09/2014.
Date of Publishing: 15/09/2014.